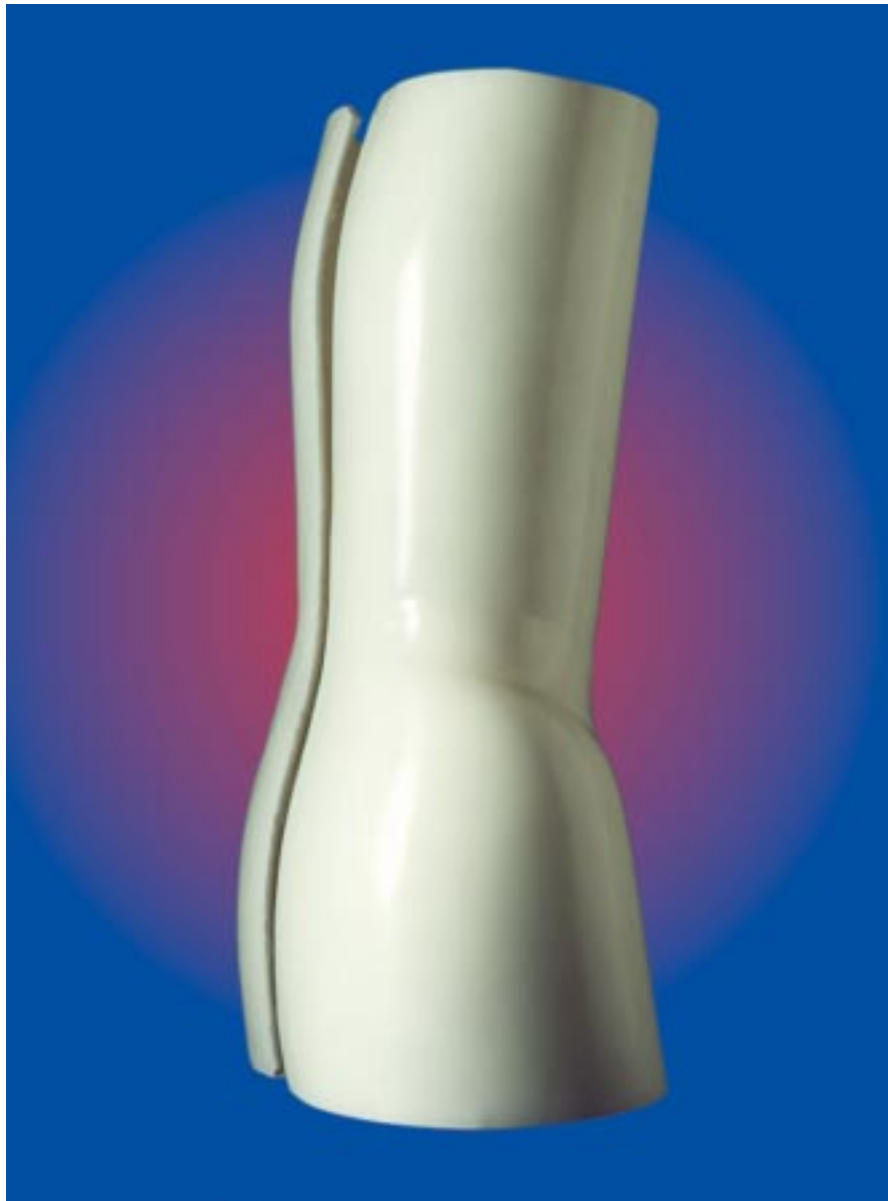

REFERENCE MANUAL FOR THE BOSTON SCOLIOSIS BRACE



BOSTON BRACE INTERNATIONAL, INC.

The Reference Manual for the Boston Scoliosis Brace is dedicated to the inventor of the brace:

M.E. "Bill" Miller
April 28, 1927 - November 5, 1992

Special thanks to the following colleagues from Children's Hospital of Boston for their time and effort expended in the production of this manual:

J. B. Emans, MD
D. Hedequist, MD
R. Miller, CPO
M. Cassella, RPT

M. T. Hresko, MD
L. Karlin, MD
M. Magin, RN
K. Ryan, RPT

J. E. Hall, MD
J. Miller, CO
C. McCarthy, RPT



BOSTON BRACE INTERNATIONAL

Tel: 800-262-2235 • Fax: 800-634-5048

www.bostonbrace.com

Table of Contents

	Page:
History of the Boston Bracing System	1
The Interdisciplinary Team Approach	2
The Boston Bracing System for Idiopathic Scoliosis	4
Terminology	4
Boston Scoliosis Brace Terminology	4
Principles of the Boston Brace	6
Brace Prescription	8
Indications for the use of the Boston Brace	8
Brace Design	10
The Brace Blueprint	11
Steps in Making a Boston Brace Blueprint	12
Brace Construction	16
Trim Lines	20
Fitting and Fabrication	22
Patient Evaluation	22
X-ray evaluation	23
Brace Fabrication and Fitting	27
Management of the Patient with a Boston Brace	29
Introduction of Brace Program to Patient and Family	30
The Nurse's Role	30
Orthopedic Surgeon Prescribes Brace	30
The Patient Picks up a Fabricated Brace	31
Physical Therapy Management	33
Instructions for Wearing Your Boston Brace	35
Brace Evaluation and Critique	38
Follow-Up Schedule	41

History of the Boston Bracing System



The Boston bracing system evolved since 1972 as a cooperative venture between Bill Miller, CPO and John Hall, M.D. It was certainly not the first bracing system to use no superstructure and chin pad or throat mold, as many earlier braces were fitted below the arms.

Very early braces were made from a combination of metal and leather but very few had superstructures. The braces made in Germany in the last century and before were well made, but were fitted like a cast, allowing no room for active correction. One model even had a jury mast coming up from the back of the brace and a spring attached to a head halter to apply longitudinal traction.

One of the earliest low braces was that of Davis in the 1860's but little is known about how it worked.

In Boston, the first below arm braces were those of Barr and Buschenfeld in the 1950's which were made of metal, leather, and canvas and contained spring loaded pads. All of these braces suffered from poor pelvic control and consequently were not able to exert the required pressure on the corrective pads. The Milwaukee brace of course could do this, has a good pelvic girdle, which could control the pelvis, and hung the pads from the superstructure which was the part of the brace which most wearers found to be objectionable.

The first braces made when Mr. Miller came to Boston were plastic girdles molded over a cast and used as the base for a Milwaukee brace superstructure. Mr. Miller then reasoned that when you buy a pair of shoes, you don't always have a cast taken but you are measured and a module is selected. He began with six standardized modules, which fit a large proportion of our patients, and these modules were used as the basis for the superstructure.

After we had been using this system for about one year, we encountered a young lady who refused to wear the brace. We bargained with her that if we took off the superstructure, she would wear the rest of the brace for her thoracolumbar curve. The module was slightly extended to put a pad just below the apex of her curve and axillary extension and she agreed to wear this. The x-rays showed that the correction was better without the superstructure and the Boston bracing system began.

For several years, we used low braces for our thoracolumbar curves and gradually extended upward until we were bracing up to T8 without a superstructure although we were still using the Milwaukee brace superstructures in some of the bracing.

When we came to compare these two groups, we found that the superstructure did not give any improved correction up to T7 or 8 and above that level, neither brace was effective in controlling the curve.

Our original concept was that the lumbar spine should be flattened to allow the best control of rotation so for several years, the modules had a flat back and a rather severely concave abdominal apron. Dr. Wally Blount visited us early in the 1970's and told us that he thought the back panel was too straight and should have some lordosis. It took us some years to realize that he was correct and this gave rise to the module with the 15° lordotic panel that has now become the standard module. The number of sizes has been greatly expanded so that most patients except those who are extremely small or extremely large or of an unusual pattern can be fitted from the module.

There are many braces throughout the country that are called Boston braces but although they have similar shapes and purposes, they should not be called Boston braces. Strictly speaking, there is not one Boston brace but a Boston Bracing System, with a Boston thoracic brace, a Boston thoracolumbar brace, Boston lumbar brace, and various other applications, all of which are specific but nothing you would simply refer to as a Boston brace.

Now that the controlled study by the Scoliosis Research Society has shown that braces can be effective, it is even more important that the braces be designed so they can control curvature. There is no way an improperly prescribed, improperly designed, or improperly fitted brace will work. Many reports of the bad results of bracing may merely be the results of bad bracing.

The Interdisciplinary Team Approach

Why a team approach?

Since its inception, the Boston Bracing System has been a collaborative effort. Each member of the team brings their unique expertise to the creation of an integrated treatment plan which addresses both the spinal deformity and the overall welfare of the patient and family. We also believe we build better braces and achieve more brace-wear compliance when multiple caregivers contribute their efforts to the design and on-going evaluation of the braces.

Why cross-disciplinary training?

Optimally, each member of the team (orthopaedic surgeon, orthotist, physical therapist, and nurse) understands enough of each other's discipline to switch roles. Orthopaedic surgeons are better able to evaluate, manage and suggest brace modifications if they understand brace design and fabrication. They are better able to evaluate the patient's progress if they possess a working knowledge of typical physical therapy exercises and have participated in breaking-in decisions, skin care and adapting the brace wear schedule to individual patient needs. Similarly, orthotists can fabricate better orthoses if they have a working knowledge of the natural history of spinal deformity, indications for treatment, associated contractures, weakness and exercises, and typical psychosocial and skin care issues encountered by other members of the team. The physical therapist needs the same overall knowledge of spinal deformity, brace design, fabrication, indications and troubleshooting demonstrated by other members of the team. The coordinating nurse generally 'pulls it all together', acting as manager, and providing specific advice for breaking-in, wearing schedules, skin care, activities and all-important psychosocial support. Without genuine expertise in natural history, indications, brace fabrication, and physical therapy, the nurse cannot speak from a position of confidence about the broad range of issues facing the patient with a spinal deformity.

Decision-making as a team

Wherever possible, we solicit the opinions of other members of the team (including the patient and family). When some aspect of management is not going well (brace fit, skin problems, loss of curve control or problems with patient compliance), the team always does much better than the individual caregiver in finding the correct solution or an innovative approach. Each team member needs to accept that the best suggestion relating to his or her discipline may actually come from another caregiver. The frequent contact and communication which occurs between team members allows an easy sharing of brace knowledge and other patient-related information.

Explaining the team approach to the family

Early on we usually explain to the family that there is a team; many families are used to the idea that the physician knows all and there is only *one* correct answer. Seeking the physical therapist's opinion on brace fit may at first seem odd to the family. Seeing each team member at each visit reinforces the concept of a unified approach.

The patient and family as team members

Perhaps the most crucial members of the team are the patient and family. Without their enthusiastic cooperation, any bracing program is doomed to failure. We try to involve the family in many ways, but by demonstrating a spirit of cooperation and role sharing among ourselves we hopefully encourage the patient and family to join the team in its effort to beat the deformity. It is essential that patient and families are part of the decision-making process, receive consistent information from different departments, and feel comfortable sharing their thoughts with the staff. Feedback from patient families enhances our program and reinforces their commitment to their child's bracing program. Patients are encouraged to share their experience with others in the clinical setting, via letters, group sessions and participation in our educational courses.

What is the routine flow of decision-making?

Usually, the orthopaedic surgeon performs a clinical assessment, interprets radiographic findings, and discusses the treatment plan and subsequent changes or modification with the patient and family. The orthotist measures the patient to select the appropriate module, then designs, fabricates and fits the brace with any necessary changes or modifications. The nurse coordinates the family's follow-up appointments; educates them on proper brace application, skin/brace care; gives the patient an individually designed adjustment schedule for breaking into the brace and assesses the patient/family's overall acceptance and comprehension of the treatment plan while establishing him/herself as the contact person for the family. The physical therapist performs a comprehensive assessment, interprets the results, designs an individualized exercise program based on the findings and alters or modifies the program as changes occur.

Can there be other successful team models?

We function in a tertiary referral center and all team members are physically located in the same clinic setting. Although we believe this arrangement to be optimal, the team approach can successfully include caregivers at several locations. If cooperative solicitous attitudes and a desire to involve other members of the team are prevalent, the 'team' doesn't have to be in the same facility.

The Boston Bracing System for Idiopathic Scoliosis

Terminology

Boston Braces utilize a prefabricated, standardized symmetrical module chosen on the basis of the patient's physical dimensions. The individual patient orthosis is constructed using the radiograph-based blueprint designed by the orthotist. To help clarify terminology, the following explanations are offered.

Module Terminology

Boston Scoliosis Module

Over the years, the standard module for scoliosis has been modified and redesigned for ease of fitting and better management of the spine and sagittal plane. Many sizes have been added. The standard module for all deformity applications is referred to as the Boston Scoliosis Module and was once designated the '15° module'. Terms such as '0°, 15°, or 30° module' are no longer used.

Custom modules:

Different sizing characteristics can be ordered for individuals whose body proportions do not match the standard modules.

Boston Scoliosis Brace Terminology

Different curves require different pad placements according to curve severity and location. In order to minimize confusion we utilize the following terminology based on the highest component of the brace:

Boston Lumbar Brace

The highest component is a lumbar pad. For use in lumbar curves (apex below L1) and lumbo-sacral curves. Usually requires a trochanter extension/pad, and lumbar pad.



Lumbar



**Thoraco-
Lumbar**

Boston Thoraco-Lumbar Brace

The highest component is a lower thoracic extension. For use with thoraco-lumbar curves (apex T12 and L1) and low thoracic curves (apex T10 and T11). Usually requires a trochanter extension/pad, lumbar pad, and low thoracic pad.



Thoracic

Boston Thoracic Brace

The highest component is an axillary extension. For use with double curves, and thoracic curves with an apex up to T6. Usually requires a trochanter extension/pad, lumbar pad, low thoracic pad, and axillary extension.

Boston Thoracic Brace with Hypokyphosis Modification

Same as the Thoracic Brace, but with the addition of cephalad posterior extensions (rabbit ears) to encourage thoracic kyphosis. For use with severe thoracic hypokyphosis or thoracic lordosis.



Hypokyphosis

Terms integral to the Boston Bracing System:

Abdominal apron

Refers to the anterior portion of the brace that extends enough laterally and cephalad to contain the abdomen and just barely cover the margins of the ribs and xyphoid process.

Axillary extension

Refers to the portion of the completed brace intended to contact the lateral aspect of upper thoracic ribs from one vertebral level superior to thoracic null point cephalad. Generally there is an open 'window' between the axillary extension and the crest roll.

Cloth gusset

Elastic cloth is affixed to an area of relief or window to provide a gradual transition between areas of pressure and relief, to provide limited pressure, or to maintain some anterior-posterior tension between the posterior and anterior parts of the brace, as between the abdominal apron and posterior uprights on a lumbar brace. Typical locations are above the iliac crest roll on both sides of a lumbar brace, or above the crest roll in the window below an axillary extension.

Iliac crest roll

The inward protruding roll of plastic and padding which comes to rest midway between the iliac crest and the lower margin of the ribs. Its function is to prevent distal or proximal migration of the brace, and to aid in positioning the pelvis in a posterior directed tilt.

Module

Refers to the prefabricated, symmetric, Boston Scoliosis Module. There are now a number of other thermoplastic prefabricated units available for rapid fabrication of Milwaukee braces and low profile, "underarm", or TLSO braces. These units differ in shape, materials and design from the Boston Brace Module System. (Most published results and this manual refer to Boston Braces utilizing Boston Brace prefabricated modules. If other prefabricated systems are utilized, they should not be called Boston Braces. Only in this way can we avoid confusion and continue to evaluate the relative merits of different systems.)

Posterior superior extensions ('rabbit ears') - "Hypokyphosis Modification"

This term refers to the cephalad extension of the posterior plastic proximal to the inferior border of the scapula. The purpose of these extensions is to better control severe hypokyphosis by applying a forward-directed force to the upper thoracic spine.

Thoracic extension, thoracic pad

Refers to the module plastic and pad extending cephalad from the iliac crest roll and intended to contact lower thoracic ribs.

Trochanter extension, trochanter pad

Commonly, plastic is left extending caudad to cover one greater trochanter. When needed, a pad is also used on the inner surface of the extension. The trochanter extension is essential to provide balance for the brace and avoid sideward tilting relative to the pelvis. Generally, the trochanter extension is placed on the side toward which L5 tilts.

Principles of the Boston Bracing System

Overview

Each individual Boston Brace should be conceived and constructed according to a basic set of principles outlined in this manual. By consistently using these principles, we believe that braces of the highest caliber will be constructed. We feel strongly that only braces that are constructed with the Boston Scoliosis Brace module according to these principles should be labeled “Boston Braces”. The principles of fabrication of the Boston Brace can be listed as follows:

- Standardized symmetric module
- Brace blueprint
- Lumbar and pelvic flexion
- Active and passive curve correction
- Pad pressure at the apex and below
- Relief opposite every area of force
- Force couples
- Coordinated physical therapy program
- Team approach

Standardized symmetric module

Prefabricated standardized symmetric modules were original to the Boston Bracing System at its inception. The fabrication advantages to the orthotist in terms of saving time, space and fabrication are obvious. Perhaps more importantly, a symmetric module per se tends to correct the asymmetric spine toward normal. By freeing the orthotist from the fabrication steps involved in converting a cast to an orthosis, more of the orthotist’s time is freed up for the brace blueprint and planning. We believe that the time and energy expended in brace design and adjustment will be reflected in improved correction.

Brace Blueprint

A brace blueprint is performed for each patient. The blueprint allows the application of Boston Brace principles to the individual patient and allows the orthotist to convert the symmetric module to an individual orthosis based on the individualized design. The brace blueprint, of course, requires the patient’s x-ray. The brace blueprint focuses attention on the status of individual vertebra and we believe allows for a much more accurate design and placement of pads. Fabrication of Boston Braces without the brace blueprint frequently results in pads that are inappropriately placed in spite of extensive experience on the part of the orthotist. At the conclusion of brace construction the brace can and should be compared to the original brace blueprint. Every portion of the brace should have a function as expressed on the brace blueprint.

Lumbar and pelvic flexion

The Boston Brace scoliosis module is designed with a moderate degree of lumbar and pelvic flexion. This has been a basic Boston Brace principle since its inception and is a fundamental part of the design of the Boston Brace. The rationale for lumbar flexion is several fold. By flexing the lumbar spine and pelvis a better grip can be obtained on the pelvis itself and a more stable foundation is made available for the rest of the brace. By placing the lumbar spine in flexion, the mid-section of the lumbar spine moves posteriorly where it is more accessible to lateral pressure and derotating pressure. Several studies have also shown that lumbar flexion per se causes an improvement in lateral curvature in the lumbar spine.

Active as well as passive correction

Passive correction is a fundamental principle of any brace. Several principles of design in the Boston Bracing system enhance active correction as well as passive correction. Wherever correction is sought, an area of “relief” is provided opposite the area of pressure so that the spine or body (in theory at least) can shift into the area of relief. In-brace exercises are also emphasized in the coordinated physical

therapy program to enhance active correction. The patient is taught to pull away from the pads while in the brace both to provide more correction and skin relief. Wherever possible, the brace is kept to a minimum to allow normal motion of the trunk and spine outside the area of treatment.

Pad pressure at the apex and below

Empirical evidence and mathematical modeling dictates that pad pressure should be at the apex of the curve and below for nearly all deformities. In the thoracic spine this is interpreted as pressure in the mid-axillary line at the apical rib and below. Analysis of the brace blueprint will reveal that pad pressure above the apex is in theory transmitted to vertebra that are already tipped toward the opposite side of the spine. Mathematical modeling confirms this empirical observation. Over the last decade virtually all bracing systems have also come to this conclusion and shifted the placement of pad pressure to the apex and below rather than centered on the apex.

Relief opposite every area of force

Boston brace principles dictate that opposite every force there should be an area of relief so that the trunk may shift. In most cases it is not necessary to actually heat relieve a void area since the Boston Brace modules are already symmetrical and they are being fitted to an asymmetrical torso.

Force couples

Rotational deformity is an important component of scoliosis. In addition to emphasizing lateral curve correction, the brace blueprint analyzes rotational deformity and several areas of the typical Boston Brace emphasize correction of rotational deformity. We believe that the application of rotational forces is potentially much more effective when “force couples” are used. Thus, for every rotational force applied another force opposite the desired center of rotation, in the same rotational direction, is applied to enhance the rotational force. Thus an anteriorly directed derotating force in the lumbar spine is counter balanced by (coupled with) a posteriorly directed force in the anterior abdomen. Where possible, two areas of relief opposite these forces should be provided.

Physical therapy

An individualized exercise program is recommended for patients wearing braces. Exercise selection is based on the results of an individual evaluation. A well designed, realistic home exercise program helps patients to successfully wear his/her brace, continue to participate in activities and help to improve the overall positive outcome of the brace program. Some individuals have asymmetric hip abduction contractures, or other abnormalities such as thoracic hypokyphosis that require specific attention. Nearly all patients require hip flexor stretching to adjust to the lumbar flexion imposed by bracing. In-brace exercises are taught to enhance curve correction, and conditioning exercises are designed to counteract the potential negative effects of full time bracing

Team approach

The team approach is emphasized in brace construction, brace application and especially management of the brace and patient over time.

Summary

The Boston Bracing System has evolved over the years but few of these principles have been significantly altered. We believe that this list of principles can be applied to virtually every idiopathic scoliosis deformity. If the Boston Brace principles are ignored, we believe that a far less effective brace will result. We encourage the course participant to continue to refer back to the principles of the Boston Brace when evaluating recently fabricated braces. One should be able to look at a Boston Brace and check its correspondence with the blueprint, demonstrate the ways in which lumbar and pelvic flexion are achieved, active and passive correction achieved, force couples demonstrated, and make sure that pad pressure is at the apices and below. There should be a demonstrable area of relief opposite most areas of pressure and force. The brace should reflect the efforts of the entire bracing team.

Brace Prescription

Indications for the use of the Boston Brace

Curve Magnitude

The goal of the Boston Bracing System is to allow non-operative treatment of scoliosis by preventing progression of the scoliosis in the growing child. A better understanding of the natural history of idiopathic scoliosis has refined the indications for brace treatment. Brace treatment is begun when the likelihood of progression of scoliosis is high. The patient with a mild curve near the completion of growth is unlikely to have further progression of the scoliosis and probably does not benefit from brace wear. The pre-adolescent with a moderate scoliosis (curvature $>30^\circ$) is at significant risk for progression of the scoliosis and may derive great benefit from brace wear. The adolescent with a 45-degree curvature and growth remaining may achieve curve control with bracing or may better be served by surgical treatment. In general, for the adolescent with a curvature 30-45 degrees and growth remaining, brace treatment is indicated and will stop progression in 50% of patients, improve curvature in 30% and curve progression will continue in spite of bracing in 20%. Bracing large curves in the younger child may delay surgery and allow further spinal growth before fusion. In juvenile idiopathic scoliosis, brace wear is initiated when the curvature exceeds 20° . In the adolescent or late onset idiopathic scoliosis, the following guidelines are suggested:

APPROXIMATE GUIDELINES FOR BRACE TREATMENT OF ADOLESCENT IDIOPATHIC SCOLIOSIS <i>(Juvenile curves should be braced much earlier- probably if over 20°)</i>	
$0^\circ - 20^\circ$	Observe for progression
$20^\circ - 25^\circ$	Brace if substantial progression documented and large amount of growth remains, otherwise observe
$25^\circ - 30^\circ$	Brace if progressive and growth remains
$30^\circ - 40^\circ$	Brace if growth remains
$40^\circ - 45^\circ$	If growth remains, consider bracing if all prognostic factors favorable- a gray zone* – surgery may be a better choice for some.
* by 'gray zone' we mean that the choice between brace and surgery is not 'black and white', rather depends upon factors other than just the magnitude of curve.	

Curve Location

All braces work best for curves with apices in the mid-section of the spine and for single curves. We believe the Boston Bracing system is usually effective in treating curves with an apex at the level of T-6 to L-3. Curvatures with apices outside of these limits cannot usually be effectively treated with a Boston Brace. We think it is open to question whether adding a superstructure helps to control curves with apices above T6 and will typically observe any upper thoracic curve above T6 and brace any significant lower curves.

Hypokyphosis and Thoracic Lordosis

Thoracic hypokyphosis ($0^{\circ} - 20^{\circ}$ thoracic kyphosis) is a common feature in idiopathic scoliosis, and true thoracic lordosis ($< 0^{\circ}$ thoracic kyphosis) is probably a contraindication to bracing. We usually brace mild hypokyphosis with a standard Boston thoracic brace, taking care to not extend a thoracic pad posteriorly and emphasizing physical therapy in the brace for posture (keeping the brace upright and the thoracic spine in kyphosis), hip flexor stretching and sometimes pro-kyphotic arching exercises. When bracing severe or resistant hypokyphosis, a modified thoracic brace is used with posterior superior extensions of the posterior uprights (rabbit ears, hypokyphosis modification) to help control hypokyphosis. Mild thoracic lordosis in the very young child can be braced with the same modification, but with limited success.

Contraindications to bracing

Severe thoracic lordosis (thoracic kyphosis $< 0^{\circ}$) is a contraindication to brace treatment of adolescent idiopathic scoliosis. All braces that apply transverse forces with lateral pads push the spine via a rib articulation and may worsen the lordotic spine. Surgical treatment is recommended for progressive curves with true thoracic lordosis.

Persistent worsening of hypokyphosis or thoracic lordosis while in brace treatment is a contraindication to continued bracing. Commonly hypokyphosis is at first worsened with initial brace application, but can be remedied as noted above.

Major psychological reaction to the brace may make a bracing program a nonviable treatment option. Bracing requires the active participation of the patient and the family in order to achieve a good result. Major psychological reaction in the adolescent requires coordinated care to prioritize medical issues with the family of the patient.

Massive obesity may make effective bracing for scoliosis impossible. The brace is designed to grip the pelvis bony prominences and apply corrective forces on the spine with asymmetric pads. Obesity diminishes the effectiveness of the pads and the bony prominences may be impossible to define. However good short and long-term correction has been achieved with bracing obese patients. A trial of bracing with assessment of short and medium term in-brace correction is advised.

The inability of the patient to actively shift the trunk away from the lateral pads may lead to severe skin ulceration. Alternative bracing systems such as the Boston Soft Body Jacket or a total contact TLSO may be of benefit for the non-surgical treatment of scoliosis in the neuromuscular patient.

Choosing the correct brace

The brace blueprint is the guide for choosing and constructing the proper brace to treat each type of scoliosis. The brace is named according to the highest curve being treated by the brace. Single curves with an apex superior to T-6 or the upper curve of a triple spinal deformity may not be effectively treated by a spinal orthosis.

The Boston Lumbar Brace is used for curvatures with apex below L1 or lumbosacral curves. The module usually requires a lumbar pad on the convexity of the curve with a trochanter pad on the same side as the lumbar pad.

The Boston Thoracolumbar Brace is used for single curves with apex at T-10 to L-1 or double curves with a flexible upper thoracic curve the upper half of which will not be braced. This module usually requires a lumbar pad and trochanteric pad on convex side of the lower curve with an opposite side thoracic pad.

The Boston Thoracic Brace is used for curves with apex of scoliosis from T-6 to T-10, or double curves. This module usually requires a low thoracic pad on the convex side of the thoracic curve, lumbar pad on the opposite side, and axillary extension on opposite side. A trochanteric extension/pad may be needed on the same side as the lumbar pad.

The Boston Pro-Kyphosis Thoracic Brace is used in the patient with severe thoracic hypokyphosis (0° - 10°). This module is similar to the Boston Thoracic brace with additional posterior cephalad extension to foster thoracic kyphosis. The apex of the thoracic lordosis should be below T-8.

The Boston Bracing System may have a role in treatment of selected patients with paralytic scoliosis. The design of the brace requires that the patient have sensate skin and sufficient neuromuscular function to withdraw from the pressure points at the sites of pad placement. If the neuromuscular patient lacks either of these functions than it is recommended that the Soft SpinalOrthosis or a total contact TLSO be used.

Brace Design

Principles of Brace Design

The goal of “Brace Design” is to convert a prefabricated module useful for a number of patients, to an individual orthosis fabricated for the specific needs of one patient.

In the manufacturing of most objects, the availability of a “blueprint” facilitates the transition between an abstract design and a finished product. Likewise, in the fabrication of a Boston Brace it is helpful for the orthotist to have a “blueprint”. Using the Cobb method the physician measures the patient’s initial x-ray and the degree of curvature is documented on the x-ray. This x-ray will now become the “blueprint” for the fabrication of the brace.

In the development of a “blueprint” for a Boston Brace, basic drafting principles are used and the brace outline is drawn on the standing PA x-ray. In addition, we believe that a standing lateral x-ray is important to consider sagittal plane curvatures. *The PA x-ray should be sufficiently long to include the entire spine and the iliac crests to the anterior superior iliac spines.* It must extend laterally *beyond the rib margin* (rather than be colimated to show only the spine). It is important that the cassette is mounted vertically so that the lateral margin of the x-ray can be used as a true vertical. Alternatively, a metallic plumb line can be incorporated in the x-ray behind or beside the patient. It is important that the patient stand erect when x-rays are taken. Any leg length discrepancy should be corrected with a lift before x-ray.

The gonads should be properly shielded. If the lower level of exposure is at the ASIS, adequate visualization of the iliac apophyses is possible yet excludes the ovaries.

The Brace Blueprint

(See Blueprint on following pages.)

Vertical and Horizontal. To create a “blueprint” an orthotist must do the following:

1. Orient the radiograph and draw a center line parallel to the side of the x-ray which goes through the spinous process of S1.
2. Draw a transverse line across the superior edge of each iliac crest. If the pelvis is not level, the degree of lateral pelvic tilt at the point where the transverse line crosses the center line is recorded. This does not necessarily mean true leg length discrepancy.
3. Find a “segmental vertebral tilt” for each vertebra by drawing a line along the inferior edge of each vertebra across the center line, and measuring the angle between this line and the center line.
4. Measure a segmental vertebral tilt for every vertebra.
5. Locate the “null” point (apex) of the curve (the level at which the segmental vertebral tilt changes from right to left, or vice versa. This point is used to determine the upper level of the pad placement.
6. Locate the L2-L3 disc space and draw a line perpendicular to the center line. This line is the level of the iliac crest rolls. (draw the crest rolls in at this level). Draw the module posterior opening. Determine the width of the widest lumbar vertebra. Draw a line on each side of the center line and parallel to the side of the x-ray equal to one half of the width value.
7. Determine the tilt of L5. If L5 is tilted, draw in a trochanter pad covering the trochanter on the same side to which L5 tilts. If L5 is not tilted, do not use a trochanter extension. Exception: If L5 is not tilted, but the patient has a stiff thoracic curve that is unbalanced to one side, then consider a trochanter extension to the unbalanced side.
8. Draw the lumbar pad. Lumbar pad “full thickness” is drawn at the level of the lumbar null point and each vertebral level below. A tapered border of approximately ¾” is drawn beyond the full thickness borders.
9. Draw the thoracic pad. The pad is drawn as a medially directed force cephalad at the rib corresponding to the null vertebra and caudal to the center of the iliac crest roll.
10. Draw the axillary extension. The axillary extension is drawn as a medially directed force and an opposing force to the thoracic extension. The upper limit of the extension is determined by the most cephalad vertebra tilting into the concavity of the thoracic curve. The lower limit is drawn at the rib corresponding to one vertebral level superior to the thoracic null point. (The upper limit generally cannot exceed the T5 level.)
11. Draw the necessary derotation pads anteriorly at the level of the corresponding apex.
12. Draw in the brace module illustrating “cutouts” for areas of relief on the lateral aspects. Posteriorly, the trimlines should be sufficient to induce pelvic flexion and control the lumbar spine.

Axial Rotation is determined using the method shown in Fig. 1. (Under this figure type: in curves with +2 rotation consider the use of derotation forces.)

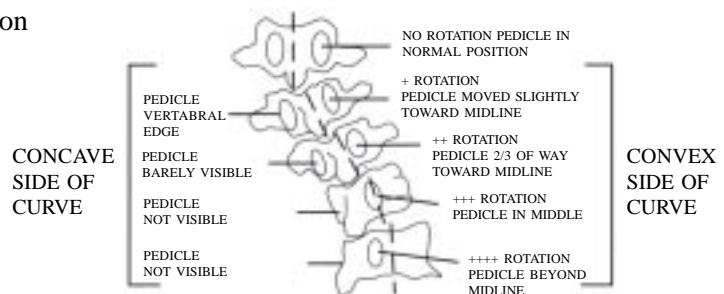
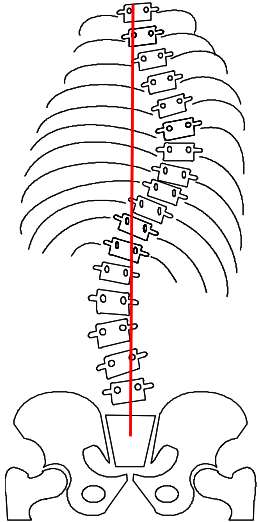
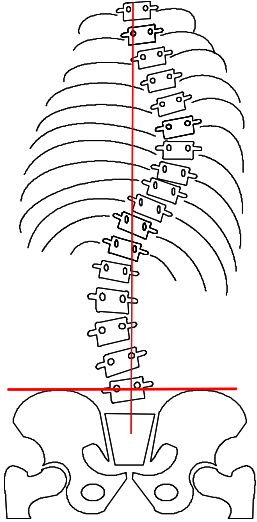
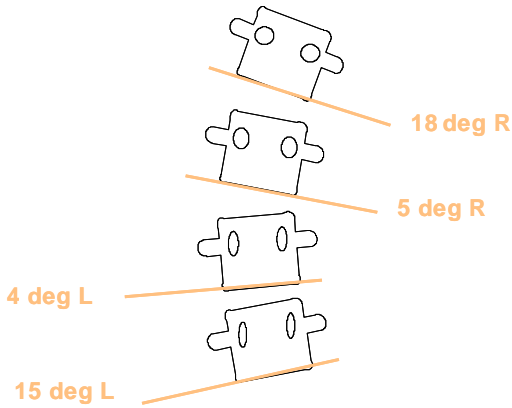
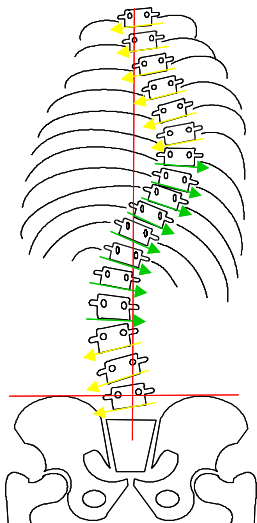
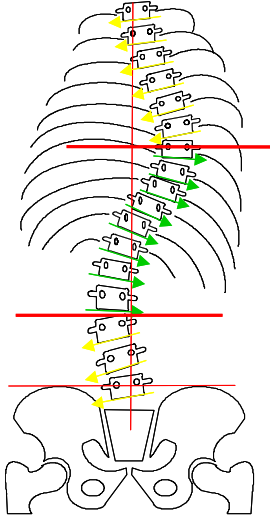
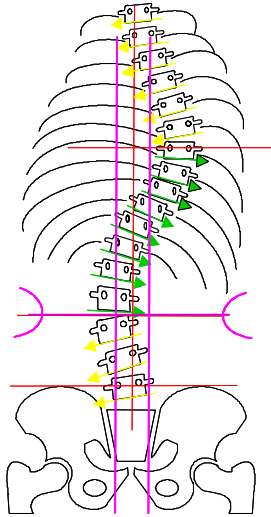
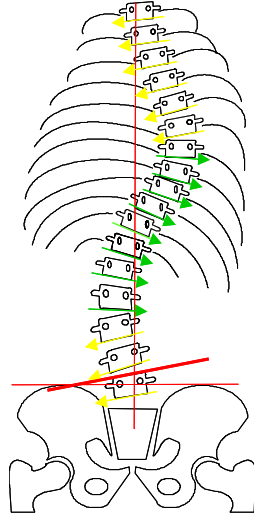
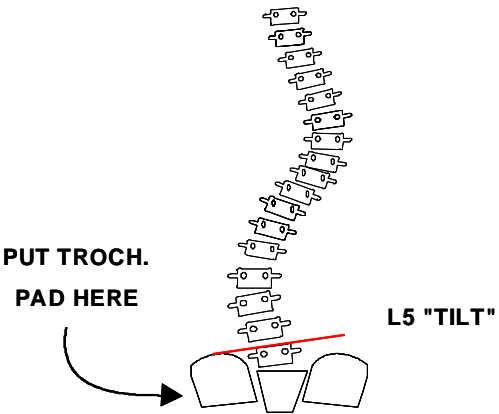
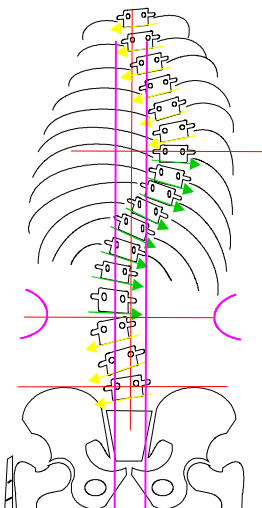
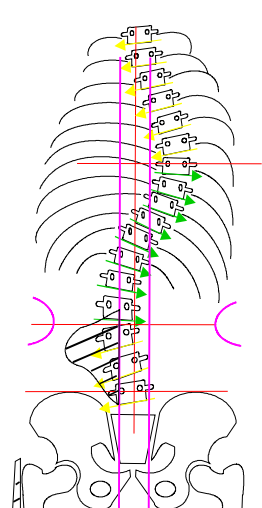
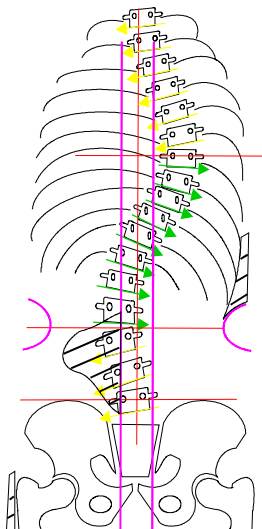
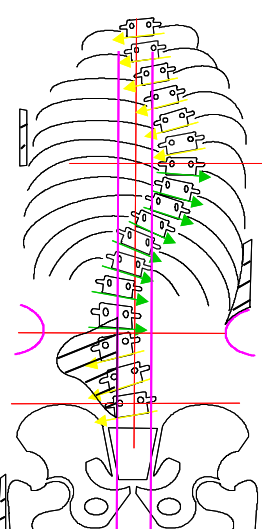


Figure 1

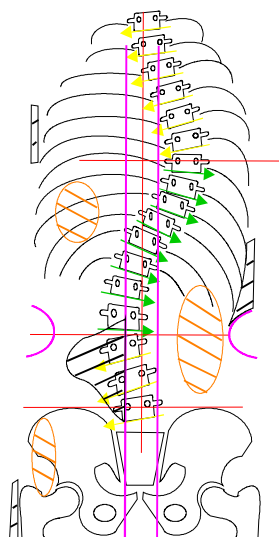
Steps for Making a Boston Brace Blueprint

Step 1	Step 2
 <p data-bbox="228 926 760 995">Orient the radiograph and draw a centerline vertically from the middle of S1</p>	 <p data-bbox="847 926 1346 1031">Draw a 'pelvic line' horizontally across the iliac crests. If very oblique, a shoe lift may be needed to level the pelvis.</p>
Step 3	Step 4
 <p data-bbox="220 1753 786 1885">Determine individual 'segmental vertebral tilt' (tilt of each vertebra relative to the horizontal) and indicate direction of tilt for each vertebra.</p>	 <p data-bbox="865 1753 1398 1917">Determine individual 'segmental vertebral tilt' (tilt of each vertebra relative to the horizontal) and indicate direction of tilt for each vertebra.</p>

Step 5	Step 6
 <p data-bbox="248 926 748 993">Determine the apex ('null point') for each curve.</p>	 <p data-bbox="841 926 1370 1062">Draw the module outline and determine the width of the posterior opening (= width of L5 vertebral body). Draw in the iliac crest rolls centered on the L2 - L3 disc space.</p>
Step 7	Step 8
 <p data-bbox="224 1753 776 1854">Determine the direction of tilt of L5. This will determine the location of the trochanter extension.</p>	 <p data-bbox="841 1753 1382 1854">Determine the direction of tilt of L5. This will determine the location of the trochanter extension.</p>

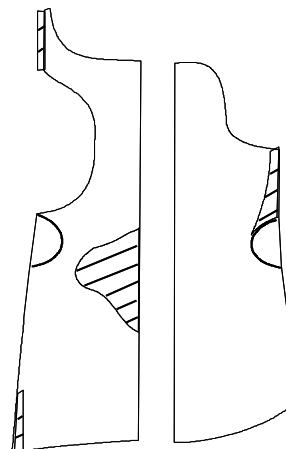
Step 9	Step 10
 <p data-bbox="235 892 714 955">Draw in the trochanter pad on the side toward which L5 is tilted.</p>	 <p data-bbox="860 892 1364 997">Draw in the lumbar pad which extends from the apical lumbar vertebra downward for all vertebra tilted in the same direction.</p>
Step 11	Step 12
 <p data-bbox="235 1732 771 1837">Draw in the thoracic pad in the mid-axillary line extending from the rib of the apical vertebra downward to the crest roll.</p>	 <p data-bbox="860 1732 1364 1869">Draw in the axillary extension to contact the ribs corresponding to upper thoracic vertebra with a segmental vertebral tilt in the same direction.</p>

Step 13



Draw in derotation pads if needed.

Step 14



Pad placement determines brace shape. Transfer pad placement to the module. Removing any unused portions of the module from the blueprint gives the final design of the module.

Brace Construction

Pad Placement

The goal of brace treatment is to prevent progression of the scoliosis by:

1. Correcting the lateral curve
2. Correcting the malrotation
3. Returning the torso to a balanced position over the sacrum
4. Properly aligning the spine in the sagittal plane

These goals are achieved by appropriate pad placement. The pads cannot float in space, but need support. Therefore, the determination of the trim lines or shape of the brace has to wait until the pad placement has been established.

Trochanter Pad (See Fig. 2)

A trochanter pad is used to correct a stiff lumbo-sacral curve and to act as a lever arm for the lumbar pad and/or the axilla extension. It is usually placed on the same side that L5 tilts toward.



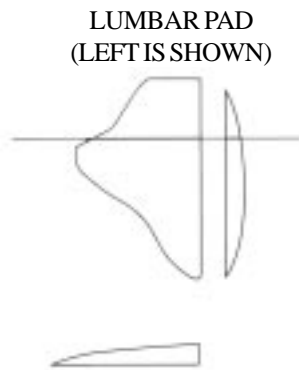
Figure 2



Trochanter Pad

Lumbar Pad (See Fig. 3)

The length (cephalad to caudad) and position of the lumbar pressure pad is determined by applying pressure to the paraspinal muscle at the level of the lumbar null point (the apex of the curve) and every vertebral body with a segmental vertebral tilt towards the convexity of the lumbar curve. Added length must be estimated for patients with increased lumbar lordosis as this results in an apparently shorter lumbar spine when seen on the PA projection. If L4 and L5 are to be included in the lumbar pad, the pad thickness should be tapered in this area so that a bridging effect between the gluteus and the upper lumbar region do not occur.



DIFFERENT SHAPES
MAY BE NEEDED

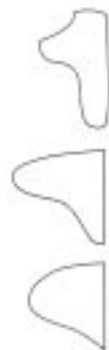
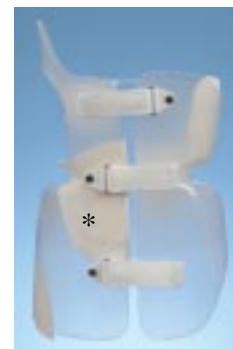
Figure 3



Lumbar Pad

Thoracic Pad (See Fig. 4)

The length (from cephalad to caudad) and position of the thoracic pressure pad is determined from the ribs which project downward from the thoracic curve. The pad is positioned from the mid-iliac crest roll level and extends superiorly to include the rib of the apex vertebra. The pad should not extend above the rib of the apex vertebra. **The thickness of the pad should not extend to the posterior vertical trim line to avoid worsening thoracic hypokyphosis.** The thickness of the thoracic pressure pad is determined by the severity of the thoracic curve and the extent to which the thorax is displaced from the center line. The pad should provide superior medial lift to the ribs under the apex, thus the pad is thicker at the bottom than at the top (a triangle in cross section).

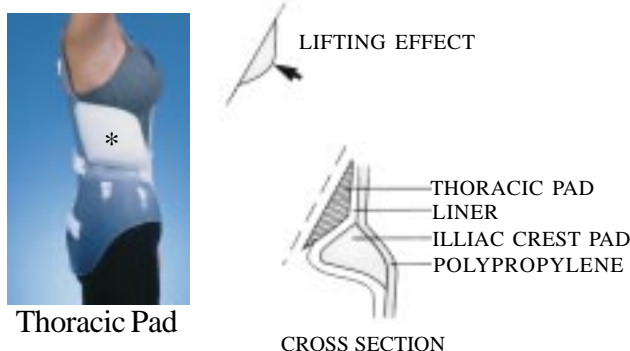
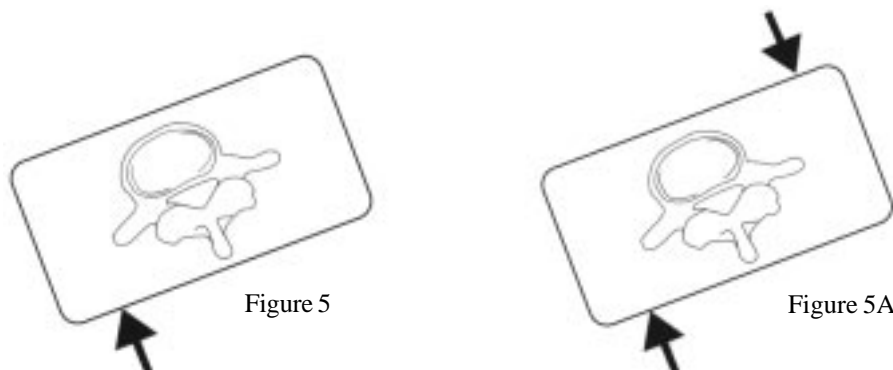


Figure 4

Derotation Pad

Axial rotation is most efficiently corrected by using force couples, that is using a pair of forces directed in opposite directions working on opposite sides of the axis. Since the Boston Brace™ module is symmetrical the **majority of derotational corrective forces are built-in to the brace.** Therefore, the need for additional derotational forces are rare. Brace mal-alignment due to severe axial rotation may require derotational pads.

In the lumbar spine, for example, a posterior pad pushing forward (See Fig. 5) is not as effective as a pair of forces as seen in Fig. 5A. A well established principle of orthotics is that correction cannot be attained by simply pressing on the soft tissue. A simple trial of such forces on your own body by an associate will demonstrate the error in this principle, because the soft tissues are bound together.



Just as the lateral forces require a relief area opposite the correcting force, rotational forces require an area of relief so that the spine can migrate axially to derotate. These relief areas can be created by an adjacent pad which draws the brace away from the body as seen anteriorly (See A, Fig. 6) or by bending the brace away from the body as seen posteriorly on the right (See C, Fig. 6).

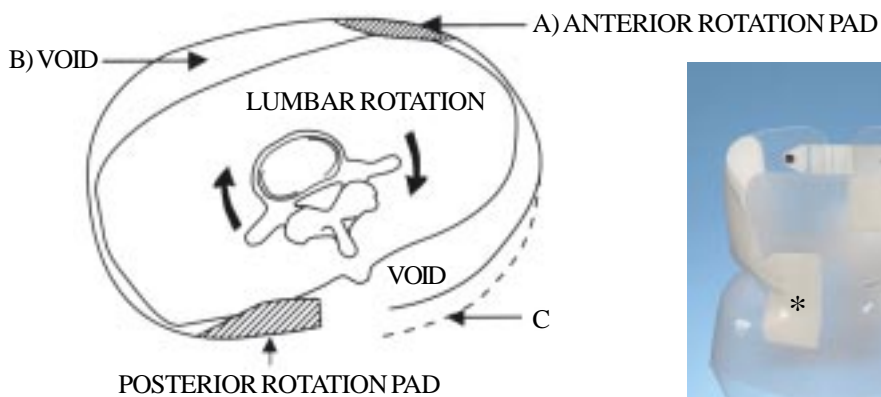


Figure 6



Anterior Lumbar Derotation Pad

In order to keep the brace from twisting on the pelvis, pads may be needed, in a force-couple arrangement, opposite to the ones used for derotation of the lumbar spine. This can be accomplished by a pad anterior to the ASIS on one side and by bending inward the lower margin of the module posteriorly (See Fig. 7).



ASIS Derotation Pad



Figure 7

Correcting the rotation at the lumbar level will exaggerate the malrotation in the thorax. Thus, counter-rotating forces may be needed to align the thorax above and to stabilize the brace on the pelvis below (See Fig. 8).

Because the ribs slope downward from back to front, the anterior thoracic derotation pad will be inferior to the posterior derotation pad on the thorax to give the appropriate force couple (See Fig 8). Thoracic posterior derotational pads are not recommended in patients who present with a hypo-kyphotic or lordotic thoracic spine.



Anterior Thoracic Derotation Pad

Figure 8

An Example of Derotation Pads

In a patient who has a major left lumbar curve with marked rotation, associated with a supple minor right thoracic curve without fixed rotation, the appropriate pads might include those shown in Fig. 9.




Figure 9

Anterior Abdominal Pad

The anterior abdominal pad is generally used to create a posterior directed force when additional lumbar pad pressure is desired or in cases where anatomical changes have occurred resulting in a brace being too large. The thickness of the abdominal pad is usually 1/2" in the middle with all four sides beveled to create a smooth transition between the brace and pad. The abdominal pad is placed superior from the top of the apron and runs full length to the inferior edge of the brace. Its width is equal to the width of the apron and its shape is similar to an hour glass. See Fig. 10 with brace.



Figure 10

Trim Lines

Lines are drawn on the module with a pencil to indicate where the plastic is cut away. These trim lines are determined from the "blue-print" x-ray. The reference points used to transpose an x-ray location to the module are the posterior limits of the iliac crest pads which usually are at the level of the L2, L3 disc space. (Fig. 11).

In order to create a shape which will allow for the **active** correction of spinal curves, an area of relief must be cut away opposite pressure pads. Therefore, the trim lines will be asymmetrical. In order to decide the location of these asymmetric trim lines, standard trim lines must be established from which the individual design will be varied. The following describes how these standard trim lines are established.

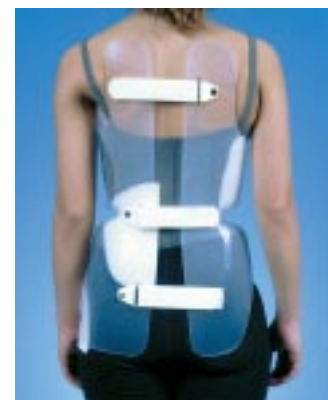

Figure 11

Trim Lines

Anterior Inferior (Fig. 12)

The anterior inferior trim line is kept as distal as the patient can tolerate. The added length below allows for more growth without replacing the module and prevents the soft tissue from being pinched between the pubis and brace. The midpoint should extend over the pubis when the patient is standing. The cut-aways for the thighs allow just 90° of flexion for sitting in a firm chair. Flowing trim lines extend from both sides of the pubis proximal to the groin crease.

Note: The cut-out at the thighs must be extended laterally to accommodate the proximal sartorius, for more comfortable sitting, and to allow free rotation of the thigh at the hip.

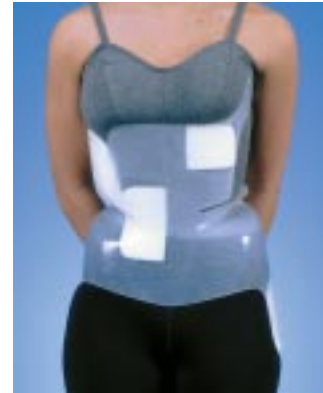

Figure 12

Anterior Superior (Fig. 13)

The standard anterior superior trim line is located at the base of the sternum to prevent impingement upon the xyphoid process. The base of the apron is at the level of the iliac crest pads and its width is approximately 50% of the width of the module at that level. The width of the apron is approximately 75% of the module at the midpoint between the base of the apron and the base of the sternum. These dimensions are adjusted to the needs of individual patients, i.e. wider at C if the ribs flare outward so that the rib margins are overlapped by the apron. Excessive apron size superiorly creates an unsightly projection. The radius of the turns in the trim line anteriorly should be at least 1/2 cm to reduce the likelihood of a fracture developing at these points.

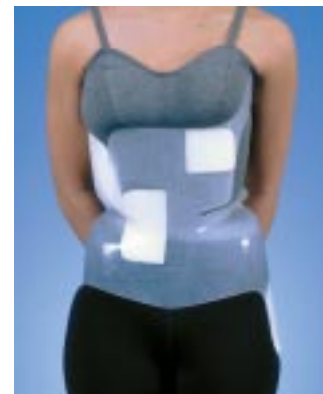

Figure 13

Posterior Inferior (See Fig. 14)

The standard posterior inferior trim line extends as low as possible, but no more than 1 to 2 cm from the seat of a hard chair when the patient is sitting with hips flexed at 90°. Establishing this trim line too high will result in increased lumbar lordosis and often unsightly bulges of soft tissue.

The Posterior Opening

The width of the posterior opening should allow the lumbar pad to press on the muscle mass over the transverse processes. The opening is first estimated by measuring the width of the largest lumbar vertebra. Later addition of pads will increase the opening appropriately.



Figure 14

Posterior Superior

The standard posterior superior trim lines originate at the level of the eighth thoracic vertebra. This height allows for a long lever arm in the reduction of excessive lumbar lordosis. The trim line flows posterior-laterally descending sharply to the top of the iliac crest pad and follows laterally along the iliac crest line to join the base of the apron anteriorly. The width of the posterior section above the iliac crest roll should not restrict lateral flexing of the spine. (See Fig. 15-A) In cases where hypokyphosis of 10° or less exists, the posterior superior trim lines should originate at the level of approximately T4. (See Fig. 15-B)

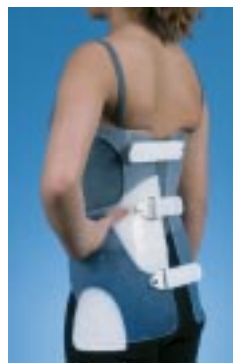

Fig. 15-A

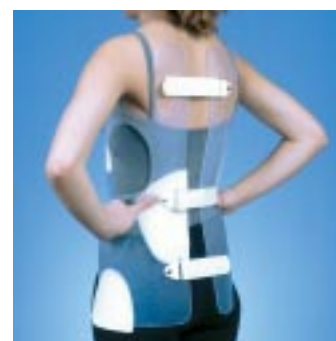

Fig. 15-B

Lateral Inferior (See Fig. 16)

The standard lateral trim line flows from the anterior inferior line passing approximately 1 cm above the top of the trochanter, curving down to the inferior posterior line.

If the patient has a lumbo-sacral curve which results in her being off balance to either side, added leverage by the module can be achieved by extending the lateral inferior trim line distally to cover the greater trochanter. A trochanter extension can be used to stabilize the brace to get additional force on the vertebral column above the module in stiff curves. The trochanter extension is placed on the concave side of a lumbosacral curve. A trochanter extension will stabilize the brace whether the patient is sitting, standing or walking. When a trim line is extended distally to cover the great trochanter on one side, the opposite inferior line should be trimmed proximally 1 cm above the greater trochanter (sufficiently high to prevent impingement on the trochanter when the patient leans maximally away from the extended side).

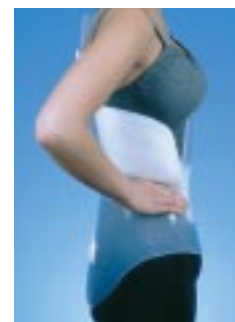

Figure 16-A



Figure 16-B

Lateral Superior

If a thoracic pad is needed, the lateral superior trim line is left proximal to contain the pad. In some cases, the thoracic extension is left on the brace with no pad.

Axilla Extension (Fig. 17)

The axilla extension is part of the module and not a pad. The axilla extension is used when there is a positive segmental vertebral tilt for the vertebrae above the thoracic null point and when the upper thoracic segment is aligned to the opposite side of the lower thoracic vertebrae in relation to the vertical center line. The axilla extension may also be used in rigid thoracic curves.



Figure 17

Fitting and Fabrication of the Boston Brace

PATIENT EVALUATION BY THE ORTHOTIST

Background

Idiopathic scoliosis usually occurs as a painless deformity in the pre-adolescent child which has been noticed on routine screening evaluation at school or by the pediatrician. The incidence of idiopathic scoliosis requiring brace treatment in girls is approximately eight times that of boys. Frequently the family history will reveal first degree relatives also with scoliosis which required treatment. The age of onset of scoliosis is variable but the major period of worsening of the curvature is correlated to the major adolescent growth spurt. The high probability of the curve progression with the adolescent growth spurt is often an indication to initiate a bracing program.

Physical Assessment

Review the patient clinically. The physical examination of the child with scoliosis should always involve the presence of a parent or same sex chaperone. Have the patient undressed enough to really see the spine, hips and trunk - a bathing suit is ideal- or stockinette can be used over underwear to make the patient comfortable, yet allow an examination. Stand back and observe for asymmetries. Are the iliac crests, waist, arms and shoulders level? Place your hands on the iliac crests to assess pelvic obliquity and leg length discrepancy. The alignment of the pelvis can be determined by palpation of the anterior and posterior iliac spines; the pelvis should be level to the floor while the patient is in double leg stance. Pelvic obliquity can also be assessed by the use of measuring blocks placed under the short leg until the iliac crests are level. Pelvic obliquity can have many bony causes: a flat or small foot, a short leg, or an underdeveloped or malformed pelvis on one side. Pelvic obliquity can also be caused by asymmetric hip flexion contracture, hip adduction or abduction contracture, or even an ilio-tibial band or knee flexion deformity. Pelvic obliquity due to infra-pelvic deformity (leg length discrepancy or joint contracture) or intra-pelvic deformity (sacral hemigenesis or iliac dysplasia) may require the use of a lift (if there is true leg length discrepancy), physical therapy (if there is a hip flexion or abduction contracture), to correct the deformity. Anatomic leg length are measured from the anterior superior iliac spine to the medial malleolus. A leg length discrepancy of greater than ½ inch usual requires a shoe lift to level the pelvis prior to bracing.

Check the patient's tissue tone and postural habits. The general body shape should be observed for height/weight proportionality. Are there any prominent bony areas that must be relieved of excessive pressure? The physique of the child may present brace wear problems. For example, obese children are difficult to fit due to soft issue impinged in the brace and failure of the brace to control the pelvis while the excessive slender child presents a challenge in dealing with body prominences such as in Marfanoid patients. Bony prominences at the sternum (pectus carinatum), posterior ribs (razor back deformity) or at the iliac crest should be noted and addressed at the time of brace fitting.

Observe for cafe au lait spots on the skin that may suggest that the scoliosis is related to neurofibromatosis. Unusual skin malformation such as with vascular malformation syndromes may require alteration in the standard brace design. Foot deformity, such as a cavus foot or unilateral clubfoot, may be a manifestation of intraspinal lesions causing muscle imbalance. Neurological examination of muscle strength, sensation, and reflexes should be performed.

Particular attention should be paid to the examination of the hip muscle. Hip flexor tightness will impede proper brace wear and requires a physical therapy stretching program. The ‘Thomas Test’, extension of the hip while lumbar flexion is maintained by ipsilateral hip flexion, is the standard test to assess for hip flexor contracture. Similarly, the ilio-tibial band and the hamstrings should be examined for tightness (refer to physical therapy section).

Palpate the spine and observe the suppleness of the curves. Note the rib hump in the thoracic area and/or of the fullness in the lumbar area at the transverse processes at the convexity of the curves. Spinal examination is carried out to observe the sagittal shape (lateral view) and the coronal (frontal) shape. The normal sagittal shape of the spine is characterized as cervical lordosis, thoracic kyphosis, lumbar lordosis, and sacral kyphosis to balance the head and shoulders over the pelvis. Alterations of the normal pattern are seen in spinal deformity such as idiopathic scoliosis where the thoracic spine becomes relatively lordotic (either hypokyphosis or true lordosis) and the cervical spine has a diminished lordotic curve. Severe hypokyphosis is addressed by the use of posterior-cephalad extensions (“rabbit ears”) with the standard Boston Brace. Excessive kyphosis associated with scoliosis is an atypical pattern. Coronal plane deformity of the spine (scoliosis) is the prominent feature of idiopathic scoliosis. This is noted on examination of the spine by a lateral shift of the thorax from the normal position (directly above the sacrum in the erect position). For the right thoracic pattern of scoliosis, which is the most common pattern, the lateral shift is accompanied by shoulder elevation on the same side and a waist crease on the opposite side. Deviation of this pattern suggests the presence of additional spinal curves so that the double thoracic pattern will have shoulder elevation opposite of the right thoracic lateral shift and the double pattern of thoracic and lumbar curves will show minimal waist asymmetry. The lateral deviation of the spine in idiopathic scoliosis is associated with rotational deformity characterized by a rib hump in the chest or para-vertebral prominence in the lumbar region. The rotation deformity is best seen during the forward flexion test (Adam’s forward bend test) and can be quantified with a scoliometer as the asymmetric trunk rotation angle.

The findings of the physical examination of the spine should be compared to the radiographs to assure correct identification of the location of the curves and correct labeling of the radiograph (this is particularly important for the atypical left thoracic curve which requires brace pad placement opposite to the usual positions).

Evaluate the patient’s and parent’s attitudes toward bracing.

X-RAY

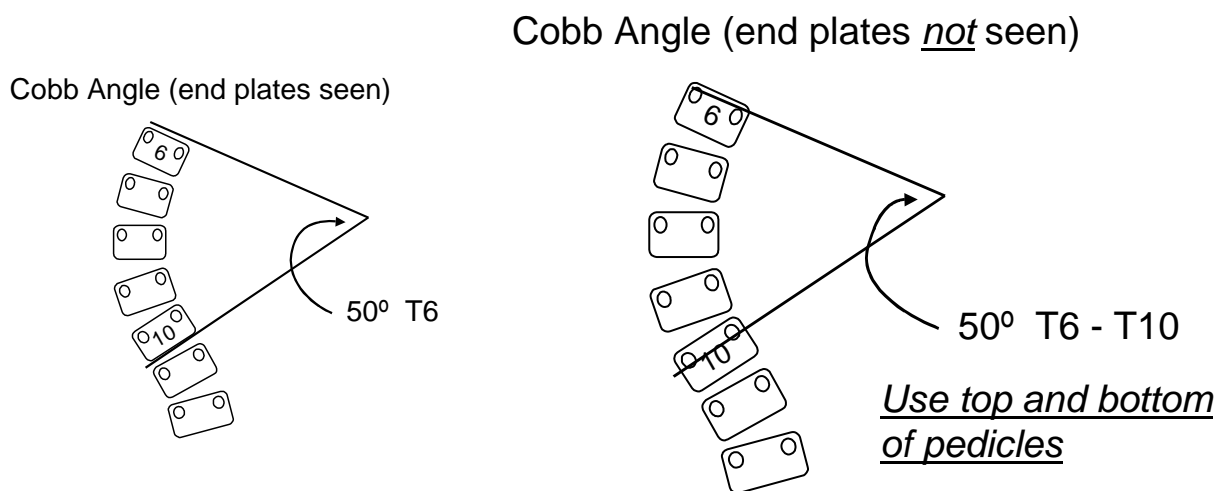
The x-ray is an important tool for the orthotist when treating scoliosis. It is far too easy to be misled by palpation of the spine. Exact curve apices can only be determined by the use of x-rays. A full complement of initial and follow-up films must be available whenever the orthotist sees the patient. Radiographs should be made without a breast shield so that the ribs may be seen to plan and observe the location of thoracic pads of the brace. Radiation exposure can be minimized by the use of the posterior-anterior projection and the use of “fast” radiographic film. It is optimal to have the entire spine on a three foot cassette radiograph. Flexion-extension and lateral bending films are not used for the construction of the brace but may at times be helpful in the decision to start bracing in the patient with a large curve when the alternatives of bracing or surgery are being considered.

Anterior-Posterior (or PA) View

The “standing” anterior-posterior x-ray is placed in a view box with R on your right and L on your left, viewing the x-ray as if you were looking at the patient’s back. The rotated pedicles demonstrate rotation of the vertebral body and are most important when analyzing for proper pad placement. Differences in the size and shape of the two iliac crests must be considered when reviewing x-rays. Vertebral bodies and disc spaces are checked for wedging and the apex of the curve or curves are noted and recorded. Observe the extent of iliac apophyseal capping and closing of the vertebral ring apophysis to get an idea of remaining growth. This may affect the frequency of the follow-up visits.

Lateral View

The “standing” lateral x-ray demonstrates the degree of lordosis and/or kyphosis. Normal thoracic kyphosis measures 20-45 degree by the Cobb method. Spondylolysis or spondylolisthesis may be seen in the lower lumbar spine. The level of deformity is seen and the forces anticipated to correct this abnormality. Should there be true lordosis in the thoracic area, (normally a contraindication for bracing) forces will be needed to alter this deformity. Imagine a line going through the axilla and trochanter which will reveal the severity of the unbalanced curve or curves. This pre-bracing documentation is necessary if, after treatment, the patient develops thoracic lordosis.

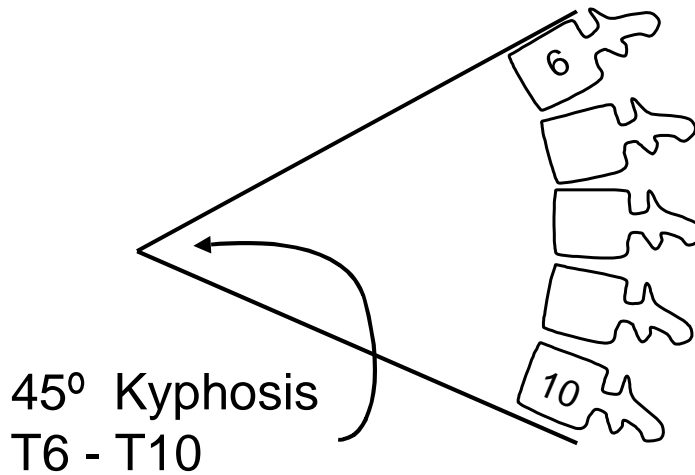


Cobb angle measurement

This is the favored method of measurement of the spinal curvature. With a straight edge, the cephalad and caudal vertebrae of each curve are defined. Perpendicular lines are constructed to allow measure of the angulation on the radiograph for documentation and comparison in the future. This method may be used to measure the frontal deformity (scoliosis) or the sagittal deformity.

The same technique can be used in the lateral X-ray to measure kyphosis and lordosis:

Cobb Angle for Kyphosis, Lordosis:

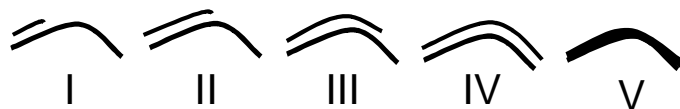

Growth, Maturity Assessment

Age at presentation is a major risk factor for progression of scoliosis. The more growth that remains, the more likely the curve is to continue to worsen. Growth is completed by most girls at age 15 and age 17 in boys. An estimate of skeletal maturation can be made from observations of the iliac apophysis ossification and fusion of the growth plate. The Risser staging system divides the ossification center into quarters and growth is assumed to occur from an anterior to posterior direction until skeletal maturity.

Assessing maturity, growth remaining:

- Chronologic age
- Menarche
- Bone age
- Risser sign
 - ossification of iliac apophysis:



The Risser staging can be quite variable when compared to other methods of estimation of skeletal maturity. Skeletal age as determined by a wrist and hand radiograph compared to standards of skeletal maturation is a more accurate method of assessment of remaining growth. Additional accuracy in estimation of remaining growth can be obtained with serial measurements of incremental growth in height over time and assessment of the physical signs of puberty (Tanner staging).

Patient Measurement and Selection of an Appropriate Pelvic Module

The blueprint should be available at the time of measuring and be reviewed frequently during the application procedures.

1. Fashion stockinette to the appropriate width and length. The stockinette over the underwear preserves the patient's modesty and provides a sense of security.
2. Ask the patient to bend her knees and draw in a breath while the measurements are being taken. Snug metric circumference measurements of the hips are taken at a distance halfway between the greater trochanter and the pubis with the tape measure dipping posteriorly at the level of the apex of the buttocks. A very tight measurement is taken at the waist depressing the soft tissue so that the iliac crest pads can form a solid purchase over the pelvis. The final circumferential measurement is taken snug at the level of the xyphoid.
3. Select the pelvic module size from the manufacturer's size chart with reference to the patient data sheet.
4. The waist measurement is most important and should be used first to determine the proper size, then the hip circumference. Due to the flexibility of the pelvic modules they can be 2 cm larger or smaller at the inferior and superior borders.
5. In the selection of the proper module for the correction of a severe lumbar curve, there should be no overlapping at the waist during the initial fitting.

BRACE FABRICATION AND FITTING

ESTABLISHING INITIAL TRIM LINES

1. Initial trim lines should be drawn on the module. See the blueprint guidelines for the location of these trim lines.
2. Check out your blueprint trim lines with your clinical findings. You may need to make alterations.

INITIAL TRIMMING AND ATTACHING FASTENERS

1. Drill 1/4" holes at the base of the anterior apron. Use a sabre saw to remove excess material.
2. Attach buckles and straps at the iliac crest rolls and at the level of the posterior superior iliac spine. Allow enough space from the posterior opening when attaching straps and buckles so that reinforcement bars can be added as needed.

A. Initial Patient Fitting

1. Check that the iliac crests are equal (if not, equalize any true leg length shortening with a shoe lift).
2. Sit behind the patient and reach around them to don the pelvic module. In some cases, due to breast development, it may be necessary to remove some polypropylene from the anterior-superior margin.
3. Exert a medial force on the module with your hands and force it down on the iliac crests. Don the module. Have the patient slightly flex their knees and draw in their abdomen. Retighten the module from top to bottom. Do not be concerned if the posterior opening is not parallel at this point in the fitting.
4. The posterior opening should not be greater than the width of the largest lumbar vertebra. Use a smaller or larger module if the posterior opening is not appropriate.
5. Draw trim lines with the module on the patient according to the blueprint and the section discussing standard trim lines on page 21.
6. Remove the module from the patient for intermediate trimming of excess material.

B. Intermediate Patient Fitting

Repeat the first six steps of the initial patient fitting procedure (secure the module with fasteners, not tape).

C. Establishing Final Trim Lines

When the module is properly tightened, the patient should be forced to stand with their lumbar spine semi flexed, and will probably complain of being thrown forward. Complete excessive reduction of lumbar lordosis is not necessary. Ask patient to sit on a firm chair with hips flexed at 90°. In this position there should be one finger width clearance between the anterior inferior trim line and the thigh, and posteriorly one finger width between the brace and hard chair.

Repeat the steps in the establishing of initial trim lines.

1. The flesh of the back or buttocks may protrude from the posterior opening when the module is being tightened. When this occurs, pull the module away and tuck the flesh under the module. Discoloration of the skin over the abdomen, waist, and iliac crests is to be expected from a correctly fitted module.
2. There should be no impingement of normal flexion or rotation of the hip joints.
3. It should not be possible to squeeze more than one finger between the abdomen and the anterior aspect of the module. If posterior vertical trim lines are not correct, reposition the fasteners and trim excess material. If too small, change module.
4. The costal margins of the module are carefully examined to make sure no force is placed laterally above the apex rib on the convexity of the curve.
5. Patient and parent may now take a break while the final fabrication of the orthosis is being finished.

D. Final Fabrication

The sabre saw is used to remove any excess plastic outside the pencil marks.

Establish smooth flowing lines by using a belt sander. Fine sanding is necessary to prevent nicks which can lead to fatigue and fuzzing of the polypropylene and foam inner liner. All edges should be sanded at right angles to the surface of the material. A router, with a worn fine grit cone, or a flexible shaft, with a fine grain metal burring head, can be used for fine sanding.

Reinforcement of the Module

Reinforcements are usually only necessary on the posterior section reinforcing the lumbar pad. If reinforcements become necessary in other areas, the following is recommended:

Anterior Reinforcement

A midline vertical reinforcement of plastic is welded to the apron and the concavity is intentionally increased if needed during the welding. This gives better control of lumbar lordosis.

- If an anterior thoracic derotation pad is being used on the apron (see page 19, Fig. 6) this will probably need reinforcement with a diagonal bar extending upward and laterally from the mid-line vertical reinforcement.

Posterior Reinforcement

- Posteriorly, vertical reinforcements are welded along the edge of the opening on each side. These should be set laterally from the edge so if subsequent brace adjustment requires widening of the posterior opening, the reinforcements will not need to be re-welded. It is important that these posterior reinforcements are properly welded so there is an inward bend (in the center from top to bottom) on the side of the lumbar pad (thus reinforcing the pad) and an outward bend on the opposite side reinforcing the changes in the module contour. In a patient with a particularly stiff curve, the reinforcement over the lumbar pad may require a metal rod within the plastic.

Rib Gussets

A patient's ribs may protrude from the lateral relief opposite the thoracic pad, resulting in pain. To prevent this, an elastic gusset is welded across the opening of the "relief" to provide a more gentle transition from the firm plastic of the brace and yet still allow mobility of the spine.

Aerate Module

In some parts of the world any apparel is uncomfortable due to extreme heat and the wearing of an appliance becomes intolerable. Aerating the module helps make it tolerable in most areas.

- The number of 7 mm holes will depend on the climate in which the patient lives.
- No holes should be placed within 2 cm of the edge of module.
- In high stress areas of module, fewer holes are drilled.
- A hole directly over the umbilicus can create a troublesome irritation and is best avoided.

MANAGEMENT OF THE PATIENT WITH A BOSTON BRACE

TEAM APPROACH

A treatment team consisting of the orthopaedic surgeon, orthotist, nurse and physical therapist, who follow the patient in a clinical setting, makes the long-term management of the patient not only successful but also very rewarding. Patients and their families gain knowledge and support from the professional team as well as from other patients and families undergoing similar treatment.

The professional team needs to give clear, consistent and concise information to patients and their families. The team should be both sensitive and supportive and should never minimize the social impact on the adolescent of wearing a brace and appearing “different” from their peers during this crucial period.

Each team member plays an important role in the success of the bracing program:

The orthopaedic surgeon performs a clinical assessment, interprets the radiographic findings and discusses and initiates the treatment plan and follow-up with patients and families.

The orthotist performs a clinical assessment, measures, fabricates and fits the brace and provides ongoing follow-up.

The nurse coordinates the clinic, provides instruction to the patient and family in brace application, hygiene and skin care and provides the patients with a reasonable schedule for adjusting to the brace.

The physical therapist performs a comprehensive assessment, interprets the results and designs an individual exercise program based on the findings.

Each team member provides emotional support to both patients and families throughout the course of treatment. A highly motivated, enthusiastic and dedicated team will have a very positive influence on both patients and families.

BRACE PRESCRIPTION

- A. Criteria for Treatment - Structural curve patterns with documented progression over 30 degrees and remaining skeletal growth.
- B. Brace selection depends on location of the apex of each curve:
 1. Boston Lumbar Brace for lumbar curves (apex below L1)
 2. Boston Thoracolumbar brace for lumbar curves (apex at T12 and L1) and low thoracic curves (apex at T10 and T11)
 3. Boston Thoracic Brace for thoracic curves (apex up to T6)

INTRODUCTION OF BRACE PROGRAM TO PATIENT AND FAMILY

This section describes how our team approach is introduced to the patient and family.

THE NURSE'S ROLE

The Nurse's role in the care of a patient who is commencing brace treatment is multifaceted. Key responsibilities must (should) include:

- Assessment:
 - physical
 - emotional
 - intellectual
 - psycho-social
- Education:
 - patient/family on natural history of decrease process
 - goals of brace treatment
 - define each team member's role in the Boston Brace System
 - specific brace use/care
 - hygiene
 - adaptation to daily living
- Coordination - provide overall plan of patient care and follow-up appointments:
 - Appointment: Pick-Up Brace and see orthotist, physical therapist and nurse
 - Appointment: (2-3 weeks after Brace pick-up) see entire team.

Other disciplines may assume this role on other settings where a nurse is not available. The above actions are critical in successful patient care. The following outline will describe the series of events a patient and family experience once the orthopedic surgeon prescribes a brace. This will include nursing and physical therapy management.

EVENT: ORTHOPEDIC SURGEON PRESCRIBES BRACE	
GOAL: Patient/family will have a basic understanding of natural history - rationale for brace, process to obtain a brace	
INTERVENTION	ASSESSMENT/RATIONALE
Demonstrate sample brace	Clarify misconceptions the patient/family may have regarding brace appearance
Review natural history and rationale for brace treatment	Clarify / interpret information given to patient/family by M.D.
Explain process for brace measurement and pick-up	Nurse establishes self as primary nurse, support, contact person to patient/family throughout treatment
Arrange follow-up visits - see above.	Appointments are scheduled for patient before leaving the hospital
Provide names and phone numbers of appropriate team members	Family needs to know whom to call with questions once they are home.

FOLLOW-UP SCHEDULE

Appointment 7-10 days after brace prescription to pick-up brace and see:
 orthotist
 nurse
 physical therapist

Appointment 2-3 weeks later with entire team. X-ray in brace after adjustment

EVENT: THE PATIENT PICKS UP A FABRICATED BRACE GOAL: Patient/family will be able to properly apply brace, understand hygiene and the breaking in process; know when to follow up with MD.	
Brace instruction sheet reviewed with patient and family.	Allows opportunity to determine individual needs.
Proper application demonstrated A. Patient applies brace to him/herself B. Parent applies brace to patient C. Demonstrate self application (this may be a future goal if not readily able to do so)	To educate and reduce anxiety A. Encourage independence B. Assess parent's ability to apply brace C. Minimizes dependency Patient feels some measure of control
Physically assess patient in and out of brace.	Determine patient's curve pattern Determine appropriate brace pattern pad placement pad contact alignment of spine in brace trim lines observe patient's ability to move around, stand and sit
Emphasize the importance of wearing the brace as tightly as possible.	Loose fitting braces will move around, cause skin problems by rubbing and be less effective.
Demonstrate a loose-fitting and tight-fitting brace.	Patient will know how tightly to fasten brace
Mark several lines on the brace straps	If there is play in the brace, tighten past the existing marks. Never should either side of the brace meet. If so, the brace needs adjustments
Emphasize the importance of frequent undershirt changes	Patients perspire more in the brace and wet, moist undershirts can create skin problems. Changing undershirts may need to be more frequent in warmer weather climates
Have the patient wear the brace during the instruction period.	This demonstrates to the patients the difference between pink and red skin. The nurse acts as a role model for the parent handling the patient's complaints.

Have the patient put his/her clothes on with the brace	This shows the patient how well the brace can be disguised under clothing.
Suggest different styles of clothing available to help conceal the brace	This helps the patient adjust his/her body image to a more acceptable one. Patient and parents should understand that present wardrobe may fit.
Explain that the patient's body will change while wearing the brace and that waist size will diminish	This offers a positive incentive for the brace wearer.
Ask patient the number of hours per day the MD has prescribed	This assesses the patient's reaction. Helps determine patient's level of acceptance and understanding of daily routine with brace
Ask patient about his/her daily routine: A. School B. Activities C. Showering D. Bedtime E. Parent's work schedule	This allows the patient to have some control in organizing their brace schedule.
Give the patient and the parent a definite schedule including the date to first wear the brace to school	Dates give the patient and parent goals for moving from stage to stage. The first date for wearing the brace to school helps prepare the patient for what they fear most.
Discuss activities	Answering questions about gym and other activities accomplished in and out of the brace and discussing sports the patient is encouraged to remain as active as before the brace.
Review the patient's understanding of the rationale for brace wear.	The patient's emotional and intellectual response is assessed. Understanding the patient's response helps provide support for future interaction.
Encourage the patient to share any concerns related to the brace or voice any worries.	Emphasize that support is available
Coordinate follow-up appointments	Emphasizes the importance of the team

PHYSICAL THERAPY MANAGEMENT

The Physical Therapy Program is designed for each individual. The significant physiological changes which occur during pre and early adolescence require regular and systematic reviews of program content. The original design and subsequent program modifications, if necessary, reflect the positive findings from evaluations and needs associated with the type of curve and brace. In addition, consideration is given to the individual's environment and activity level.

A. OBJECTIVES

1. To perform a comprehensive evaluation and interpret results.
2. To design an appropriate treatment program based on evaluation data.
3. To apply a Boston Brace to a patient.
4. To teach the patient to sit and walk correctly in a Boston Brace.
5. To provide guidance for participation in general activities.

B. COMPREHENSIVE EVALUATION

1. Inspect patient's natural relined posture.
 - a. Posterior View
 - b. Anterior View
 - c. Lateral View
2. Measure Leg Lengths
 - a. Real
 - b. Apparent
3. Identify and locate curve or curves (clinically and by x-ray)
 - a. Major and/or minor
 - b. Degree of rotation (if present)
 - c. Apex
4. Review status of skeletal growth.
5. Assess range of motion.
 - a. Spine
 - b. All other joints
6. Assess muscle strength
7. Assess breathing pattern
8. Assess functional abilities
9. Assess pain status

Describe other related findings

C. EXERCISE PROGRAM

The selection, level of difficulty and length of time of the total program needs to be considered for precision of performance and compliance.

1. Purpose of exercise program (out of brace):
 - a. Develop postural awareness and ability to maintain corrected alignment.
 - b. Maintain and/or increase chest mobility for proper respiration.
 - c. Maintain and/or increase muscle strength as indicated.
 - Trunk (emphasize abdominals)
 - Scapulae
 - d. Maintain and/or increase spinal flexibility.
 - e. Maintain and/or increase range of motion (prevent contractures, especially in hip flexors).
 - f. Provide a good general physical condition.

-
-
2. Purpose of exercise program (in brace):
 - a. Develop postural awareness and ability to maintain corrected alignment as provided by brace (very important)
 - b. Enhance patient's comfort
 - c. Assist patient to resume previous activity level.
 - Functional
 - Social
 - Recreational
 3. Postural alignment: Done as frequently as possible, both in and out of brace.
 - a. Lumbar Flexion (posterior pelvic tilt)

This serves to maintain the anterior-posterior balance of the spine by elongating the posterior structures and enhancing the contractile elements of the anterior structures. This keeps the pelvis and lower spine in optimum alignment as the patient attempts proper trunk alignment.
 - b. Trunk Alignment

Patient attempts to align head, neck and trunk over pelvis.

D. APPLICATION OF A BOSTON BRACE TO PATIENT

E. TEACH PATIENT TO STAND AND WALK CORRECTLY IN BOSTON BRACE

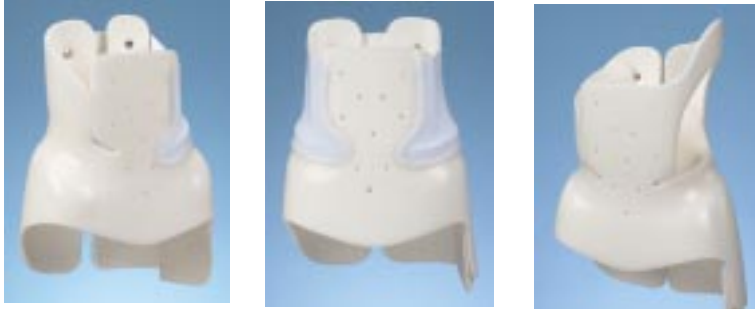Patient stands in front of mirror and assumes lumbar flexion (posterior pelvic tilt).

Patient maintains lumbar flexion while assuming erect posture.

Patient walks maintaining the above posture.

F. BRACE PICK-UP, APPLICATION, HYGIENE, HOME INSTRUCTIONS

INSTRUCTIONS FOR WEARING YOUR BOSTON BRACE



SUCCESSFUL ORTHOSIS WEARING REQUIRES YOU TO

- Wear your orthosis 18-23 hours daily within 2-3 weeks (unless otherwise specified by your Doctor).
- Take care of your skin daily.
- Wear a Boston T or a snug fitting t-shirt at all times under your orthosis.
- Properly apply the orthosis to your body.
- Clean your orthosis daily.
- Complete your exercise program daily.
- Gradually increase your daily wearing time.

APPLYING YOUR ORTHOSIS

Proper placement of the orthosis to your body will be demonstrated by the nurse. There are several methods of application. At first you will need help but eventually you will learn to do it yourself. The easiest method is described below:

- Make sure all straps are outside the orthosis.
- Place orthosis around your body by holding each side and spreading the orthosis so you can twist into it. The orthosis is stiff when new, you might need help.
- The opening of the orthosis should be centered on your back so that the bumps on the spine and the crease between the buttocks are in the middle of the opening.
- Push the orthosis down by placing hands on your hips - the sausage shaped pads (or waist pads) on the inside of the orthosis should rest just above your hips and below your ribs.
- Lean forward on to your forearms on a table, dresser, counter etc. - your helper will thread the straps through the buckles.
- Your helper applies pressure with the flat of one hand to the side opposite the buckle. At the same time the helper pulls the velcro strap with the other hand toward the hand applying the pressure.
- Secure the middle strap first, then bottom and top straps, then straighten up.

HOW TO APPLY AND TIGHTEN THE ORTHOSIS YOURSELF

- Place orthosis on your body as described above
- Thread the straps through the buckles
- Lean forward from your hips and pull straps out, down and away from the buckle side. Remember to be patient, this takes practice.

HELPFUL HINTS

- Make sure your spine and gluteal crease is centered in the orthosis opening.
- The waist pads must be above your hips and below your lowest rib.

CLEANING THE ORTHOSIS

It is important to clean the foam liner of your orthosis daily. The foam will not absorb moisture, however, perspiration will collect on it. Clean the foam with rubbing alcohol. The rubbing alcohol will disinfect the liner and quickly evaporate.

SKIN CARE

It is very important to PREVENT SKIN BREAKDOWN (that is sore, red, raw skin). The skin under the orthosis needs to be toughened up, especially where the orthosis applies the most pressure.

To Protect The Skin

- Bathe daily.
 - Apply rubbing alcohol with your hands to all parts of the skin your orthosis covers. Alcohol plus the friction of your hand on your body will toughen the skin.
 - Pay special attention to pink areas of the skin where orthosis pressure is highest.
 - Always wear a Boston T or a snug fitting t-shirt (without seams) under your orthosis (available from your orthotist).
 - Always wear underpants over the orthosis (to prevent skin breakdown around elastic band).
 - Wear orthosis as tightly as possible. A loose orthosis may rub and cause skin breakdown.
 - The use of cornstarch is often helpful in the hot weather, or on skin sensitive to alcohol.
- Initially do not use creams, lotions or powders under the orthosis. They often soften the skin.** If there is skin breakdown (sore, red, raw skin) the orthosis must not be reapplied until the skin heals (one day or more). If this happens, call your nurse or orthotist.

Sometimes the skin over the waist and hips gets darker. This is common and is not a problem. When the orthosis treatment is complete, the discoloration will fade.

BREAKING INTO YOUR ORTHOSIS

Over a period of 2-3 weeks, gradually increase the time per day in your orthosis. The following program is designed to help your skin and muscles adjust to the orthosis:

STAGE I: Wear orthosis 6 hours daily.

- Best accomplished after school and up to bedtime.
- Apply orthosis for 2 hours.
- Remove orthosis, check skin and rub with alcohol. If your skin is just pink, reapply orthosis for 2 more hours and repeat up to 6 hours total.
- If your skin is sore and red, wait 30 minutes then rub with alcohol and wear for 2 more hours up to 6 hours total.

Begin Stage I Date: _____

End Stage I Date: _____

STAGE II: Wear orthosis 10 hours daily.

- Apply orthosis for 4 hours.
- Remove orthosis, check skin, and if necessary, rub with alcohol.
- Reapply orthosis for 3 hours.
- Remove orthosis, check skin, and if necessary, rub with alcohol.
- Reapply orthosis up to 10 hours total.

Begin Stage II Date: _____

End Stage II Date: _____

STAGE III: Wear orthosis 18-23 hours daily.

- Apply orthosis before school.
- At lunchtime or 4 hours later, remove orthosis, check skin, and if necessary, rub with alcohol (your school nurse can help).
- Reapply orthosis.
- After school, remove orthosis.*
- Reapply orthosis at bedtime.
- Sleep in orthosis.

* The daily number of hours out-of-brace depends on the Stage III daily hours prescribed to you by your Doctor.

Begin Stage III Date: _____

- Once you are able to sleep in your orthosis, you have achieved your goal of orthosis wearing!
- Strictly follow the hours called for in your treatment plan.
- Make time daily for bathing, skin care, undershirt changes, and exercise.

Exercises

THERE ARE TWO SETS OF EXERCISES THAT YOU WILL BE GIVEN.

- A. One will be a set of exercises done during the time you are not wearing the brace. These exercises are done to keep your back limber and your muscles from getting weak.
- B. The second set of exercises are those which you do while you are wearing your brace. These should be done as often as you can during the day as it is these exercises which will help your brace to be more effective in the treatment of your scoliosis.

DOING THESE EXERCISES RIGHT FROM THE START WILL MAKE THE BRACE MORE COMFORTABLE.

Remember your physical therapy program - it is very important since it is the brace and exercises together that achieve the best results.

All of this together will help to make your brace treatment successful. We recommend swimming without the brace since water supports your back. For safety around the water try swimming in your brace with a buddy so you won't be afraid if you fall in while sailing. Your nurse will help you with specific instructions about water sports and other activities.

Your Orthopedic Surgeon is:

telephone #

Your Nurse is:

telephone #

Your Orthotist is:

telephone #

Your Physical Therapist is:

telephone #

BRACE EVALUATION AND CRITIQUE

CHECKOUT OF THE BOSTON BRACE

Purpose of the Checkout:

The purpose of the checkout is to review the brace design, fit and function. Brace checkout should be done when the brace is first delivered, when the patient returns for the first in-brace X-ray, and on subsequent return visits. The initial brace checkout should be done with the brace blueprint available for reference, and subsequent visits should include comparison to the most recent X-ray. The orthotist, physical therapist, nurse and physician should all be competent in brace checkout.

Patient standing

Watch the patient apply the brace and correct any errors. A clue as to the real frequency of brace wear can be noted by the ease with which the patient applies and removes the brace.

POSTURE

Sagittal Plane

Examine the patient standing with the brace on, viewed from the side.

Hips and Knees: Does the patient stand with hips and knees flexed? (Common with a new brace which diminishes lumbar lordosis). This suggests the need for hip flexor stretching and postural awareness. If one knee or hip is flexed, the contracture may be asymmetric or there may be a leg length discrepancy.

Thoracic Spine: Does the patient stand with the thoracic spine above the brace extended in hypokyphosis or lordosis? This too is common with a new brace and suggests the need for hip flexor stretching, postural awareness and perhaps prokyphotic exercises for the thoracic spine.

Coronal Plane

Examine the patient standing with the brace on, viewed from the front or back.

Patient Tilt: Is the patient listing to one side or standing with one knee flexed? If so, this may be due to a leg length difference. Reexamine the X-ray and the patient. A shoe lift to compensate for the leg length may be needed. If the leg lengths are equal and the patient still lists to one side, then see Brace tilt below.

Brace Tilt: Is the brace tilted to one side? This may mean that a trochanter pad is needed, or an existing trochanter pad is inappropriate. It may also mean that the brace is too extensive or not extensive enough. (For example, a thoraco-lumbar rather than a thoracic brace is needed, or a thoraco-lumbar rather than a lumbar brace is needed)

Trim Lines (Standing)

Examine each of the trim lines in sequence. In each case, consider why the trim line is located as it is, and whether that part of the brace is fulfilling its particular function.

Anterior Superior

Does the anterior superior trim line (top of the abdominal apron) just cover the xyphoid process and rib margins? Does it allow easy breathing and lateral bending? Does it still control the abdominal contents?

Anterior Inferior

Does the anterior inferior trim line cover the ASIS's by at least two finger breadths? Does the center just cover the pubis? If the trim lines appear too high, check to see that the brace is properly applied, and not simply riding too high. The curves should flow freely, with no sharp points.

Posterior Superior

Do the posterior superior trim lines appropriately achieve control of sagittal plane flexion / extension? The standard posterior superior trim lines should end at the level of the T8 vertebra and should allow free movement of the inferior scapular margin. A common problem noted with the standard posterior superior trim line, especially in a new brace, is worsening of the hypokyphosis of the thoracic spine above the posterior superior margin of the brace. This problem is addressed above under patient standing posture. If a prokyphosis extension of the posterior superior trim lines was used, check that they are contoured to contact the patient.

Posterior Inferior

Are there bulges of buttock tissue beneath the posterior inferior margins (too high) or excessive brace protruding from the buttock contour (too low)?

Posterior Opening

Is the posterior opening centered on the back? Are the margins parallel and is the opening approximately the width of the 5th lumbar vertebra? Check that the lumbar pad is contacting the paraspinal muscle mass and that the pressure is appropriate.

Lateral Inferior

Trochanter Pad / Extension Is the trochanter pad on the correct side (on the side toward which L5 is tilted, beneath the concavity of the lumbosacral curve)? Check that the trochanter is covered and that pressure beneath the pad is appropriate.

Opposite the Trochanter Extension Is the opposite side trimmed 1 cm above the proximal limit of the greater trochanter? Ask the patient to rotate the lower extremity and check for impingement.

Patient sitting

Examine the patient seated on a firm, flat chair, with the hips flexed at 90 degrees. The brace should not ride up or displace.

Trim Lines (Sitting)

Anterior Inferior

Check that there is room for the sartorius muscle (lateral corner of the thigh) and that the brace does not cut off circulation to the legs. The pubis should be covered in the sitting position, and the brace should not impinge on the bone.

Posterior Inferior

Is the brace as low as possible, while still leaving a 1-2 cm. space above the chair?

Checking the brace against the blueprint

Examine the brace on the patient while referring to the blueprint. Consider each component of the brace blueprint and make sure that the finished brace embodies your blueprint design.

Pads and Relief Areas:

Trochanter Pad

Is the trochanter pad on the correct side? Does it keep the brace balanced? Is the opposite trochanter free to move?

Lumbar Pad

Is the lumbar pad pressure located appropriately contacting the paraspinal muscles with the upper margin of the pad at the null point? Is there adequate relief opposite the lumbar pad?

Thoracic Pad

Does the upper margin of the thoracic pad contact the appropriate rib and does the trim line correspond to the angle of the ribs? Is there adequate relief opposite the pad?

Axillary Extension

Does the axillary extension provide pressure, yet not impinge on breast tissue or scapulae? Has the patient learned to not extend posteriorly over the proximal margin of the brace?

Rotational Force Couples

Examine each of the following for rotational control and demonstrate areas of pressure and relief:

1. Pelvis
2. Lumbar Spine
3. Thoracic Spine

Sagittal Plane

Consider whether the brace does an adequate job of contorting or at least not exacerbating deformities in the sagittal plane.

Lumbar Lordosis

There should be control of lumbar lordosis, so as to make the paraspinal muscles accessible to the lumbar pressure pad and control pelvic rotation.

Thoracic Hypokyphosis

Is the thoracic hypokyphosis helped or worsened? What design features promote this?

CHECKING THE BRACE OFF THE PATIENT

Remove the brace in order to check the patient's skin and the brace. The condition of the brace gives a clue as to how much it is used.

Brace

Brace Lining

Are the Lining and edges of the pads smooth, even, and free of glue? Is the Lining beaten down anywhere suggesting areas of excessive pressure? Check for loose edges.

Pads

Do the pad edges flow into the surrounding brace? Are the pads loose?

General

Are the straps long enough? Are there any rough edges?

Patient:

With the brace removed, check the skin.

Skin Condition

Is there excessive redness or breakdown? If irritation is present, check the brace lining. Check pelvic control if irritation is excessive over the iliac crests. Excessive motion will often cause such irritation.

Location of Skin Pressure Areas

Check the areas of hyperemic skin against the blueprint. Is the pressure located where pressure is desired?

FOLLOW-UP SCHEDULE

How often should the patient be seen in follow-up?

Follow-up schedules must often be tailored to the individual needs of a patient, but our standard regimen tries to achieve a balance between excessively frequent visits which may cost too much time from school and family, and too widely-spaced visits during which the brace may no longer fit or be adjusted properly or the patient easily lose enthusiasm for wearing the brace. When in doubt, the patient should be seen frequently. Once adapted to brace use, most patients should be seen every 3 months. Although little may appear to occur with these visits, it seems necessary to frequently validate the patient's efforts in brace usage and encourage or realistically assess their progress. If given a more remote follow-up appointment and told to 'come back sooner if there is a problem', patients rarely seem to come back for compliance and psychosocial problems, poor fit, skin irritation, etc. Yet when given an appointment for every 3 months, these issues are noted earlier and dealt with somewhat more effectively.

How often should there be radiographs?

In the past, radiographs were taken every 3 months. We now try to make each radiograph count, and would like to think that there are no 'routine' radiographs, rather each radiograph is taken to answer a specific question, or help with a specific decision. Many of our patients whose brace treatment is proceeding routinely receive only one radiograph each year.

Typical schedule for visits and radiographs is outlined on the following page.

Visit Type	Frequency	Procedures	Radiographs
Initial Visit		Evaluation, PT if stiff, measure for brace.	Standing PA and Lat
Brace pick up	2 weeks later	Orthotist delivers brace. Nurse reviews brace usage, schedule. Physical Therapist assesses, instructs exercises.	none
First In-Brace follow-up	2-4 weeks, when wearing full-time	See brace shop for final fit, adjustment, tightening. Nurse, PT and Physician review brace fit, critique, in-brace correction.	Standing PA (rarely Lateral), in brace
Second In-brace follow-up	6 weeks	All team members review brace adjustments frequently needed.	none
Routine follow-up	3 months	All team members review brace adjustments.	Standing PA (lateral if hypokyphosis a problem) either in or out-of-brace depending on physician preference. Radiograph frequency depends on many factors, but typically 6 months after brace initiation, then yearly thereafter. Wrist for bone age frequently helps in determining approximate length of time remaining in brace.
Skeletal maturity, beginning of weaning		All team members	Standing PA, spine out of brace (Wrist for Bone Age if needed)
End of bracing	1 year later	MD, PT, Nurse	Standing PA and Lateral out of brace
1 year follow up	1 year later	MD	Standing PA spine
2 year follow up	2 year later	MD	Standing PA spine
5 year follow up	5 years later	MD	Standing PA spine
10 year follow up	10 years later	MD	Standing PA spine

BOSTON BRACE FOR SCOLIOSIS™

SIZE CHART (cm)

All stock sizes available in 0° or 15° of lordosis.

Size	Hips	Waist	Xyphoid	ASIS
Juvenile				
J1	54	40	49	14
J2	58	42	51	15
J3	62	45	54	16
J4	64	47	56	17
Youth				
Y1A	66	51	55	17
Y1	67	46	56	18
Y2	71	47	60	19
Y2A	72	55	62	20
Y3	75	48	63	20
Y3A	78	57	69	21
Y4	79	51	64	23
Y4F	80	57	66	22
Y5	82	52	68	24
Y5F	82	58	68	23
Y6	84	56	73	24
Y6A	84	63	78	23
Y7	86	54	69	25
Y7F	86	60	70	24
Y7A	86	69	73	24
Y8	88	58	75	25
Y8F	88	64	75	24
Y8A	90	72	83	24
Y9	92	60	72	26
Y9A	92	63	69	25
Y9F	92	68	78	25
Adolescent				
A1	94	62	76	27
A2	94	70	84	26
A2A	96	66	75	25
A3	97	68	80	27
A4	97	76	88	27